
Surgical Management of Obstetric Brachial Plexus Palsy Secondary Deformities

Rahul K. Nath and Chandra Somasundaram

Additional information is available at the end of the chapter

<http://dx.doi.org/10.5772/58322>

1. Introduction

The objectives of this book chapter are to describe the diagnostics, clinical assesment and surgical management of obstetric brachial plexus injury (OBPI) or brachial plexus birth palsy (BPBP).

OBPI occurs during delivery process. The incidence of OBPI has been reported to vary between 0.38 and 5.8 for every 1000 live births [1-5]. The occurrence has increased despite the advances in obstetrics, and medical technology [6, 7]. Reported risk factors for OBPI include shoulder dystocia, macrosomia (defined as birth weight greater than 4500 g) [8-11]), instrument-assisted delivery, and downward traction of the fetal head [3, 12, 13]. Shoulder dystocia is the most prevalent risk factor in our patients [14]; almost all the children in our study had documented shoulder dystocia [14]. Shoulder dystocia is, therefore, closely associated with the most severe cases of permanent obstetric brachial plexus injuries [8, 9, 11]. However, permanent injury is not exclusive to large infants; 80% of the OBPI patients in our published study were not macrosomic and 43% (104/241) weighed less than 4000 g at birth [14]. OBPI that occur during breech deliveries may have a different mechanism of onset, and are more likely to be bilateral. Avulsions of the upper roots are more likely during breech than during vertex delivery [15, 16]. OBPI may also occur, although very rarely, during cesarean sections [17].

The most commonly affected roots are C5–6 (Erb's palsy), because of their more superficial location in the neck, are more vulnerable to injury. Less frequently, the entire plexus (C5–T1) may be affected [18, 19]. The injury can be simple stretch or rupture or avulsion. Most of these injuries are transient; patients recover functions spontaneously within the 3 months of life. However, a significant proportion of these children tend to retain persistent limb deficits, never recover full function and develop permanent injuries [1, 20, 21]. Unlike adults, children may have complications from even the most simple nerve injury due to the growth issues that are

present. The mildest and most common OBPI is neurapraxia; the most severe is avulsion [20, 22]. Both types of injury have the potential to result in permanent disability.

2. Diagnostics

Diagnostic tools used to identify which lesions are permanent in OBPI include computed tomography (CT), magnetic resonance imaging (MRI), myelogram, and electromyography (EMG) as well as nerve conduction velocity (NCV) studies [23-27]. Distinguishing preganglionic (avulsion) from postganglionic (rupture) lesions is critical, and can be difficult at initial presentation based on clinical examination alone in these infants [26, 28]. Our experience with MRI for pre-operative assessment of the spinal roots has been unfavorable. EMG testing is the procedure of choice for preoperative evaluation of nerve-muscle integrity.

2.1. Radiological evaluation

In order to assess bony deformities of the shoulder joint, CT or MRI images of the patients are studied before and after triangle tilt surgery. Posterior humeral head subluxation, glenoid version, and SHEAR deformity are measured from the radiographs (CT/MRI scans). Glenoid version (normal value=0) is measured as described by Friedman et al. [29] using axial CT/MRI images (Figure 1). A scapular line connecting the mid-glenoid to the medial spine of the scapula is constructed using Universal Desktop Ruler (AVPSoft.com, Voronezh, Russia). The angle formed between the scapular line and a line drawn tangential to the glenoid surface interacting closely with the humeral head is calculated and 90° is subtracted from it to measure the glenoscapular angle. Posterior subluxation of the humeral head (Figure 1) is expressed as percentage of humeral head anterior to the glenoid (PHHA, normal value=50), and calculated from the ratio of the distance between the scapular line to the anterior aspect of humeral head and the greatest diameter of the head, multiplied by 100.

The scapular deformity, also referred as SHEAR deformity is measured from the 3D reconstructions of the CT images (Figure 2). The area of the scapula visible above the clavicle is measured and divided with the total area of the scapula for both affected and normal sides. The ratio of the affected side is subtracted from that of the normal side and multiplied with 100 to obtain SHEAR deformity (normal value=0).

2.2. Clinical assessment

Shoulder function is assessed through the modified Mallet scale through video recordings of patients performing the following movements: shoulder abduction, external rotation, hands to mouth, hands to neck, hands to spine, and supination. For each functional Mallet parameter, patients are scored on a scale of 1–5 with 5 as normal function, and 1 denoting lack of any movement (Figure 3). Despite continuing improvements in diagnostic technology, at this time, the final diagnoses must be made during surgery in complex or unclear cases.

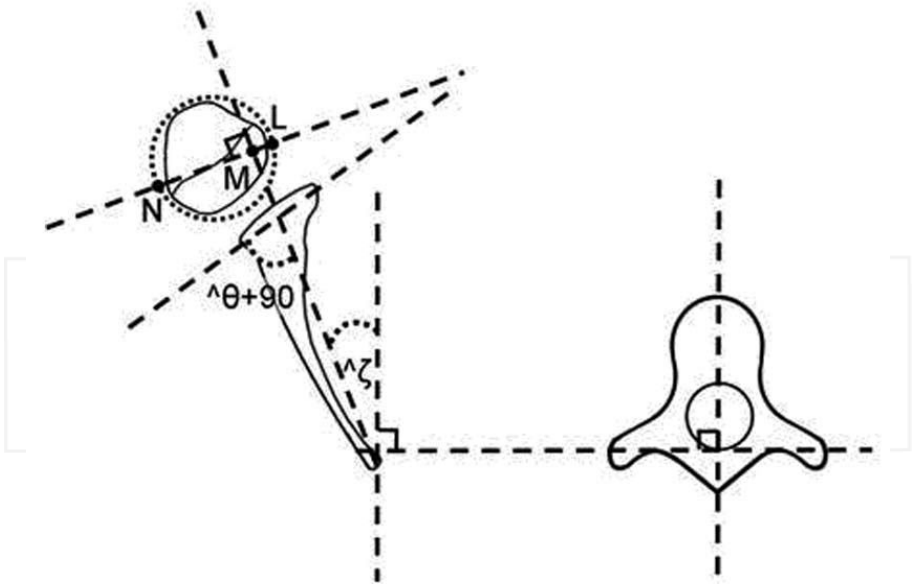


Figure 1. Schematic drawing showing the method of calculating glenoscapsular angle (glenoid version θ), posterior subluxation of the humeral head and spinoscapsular angle (ζ) [40].

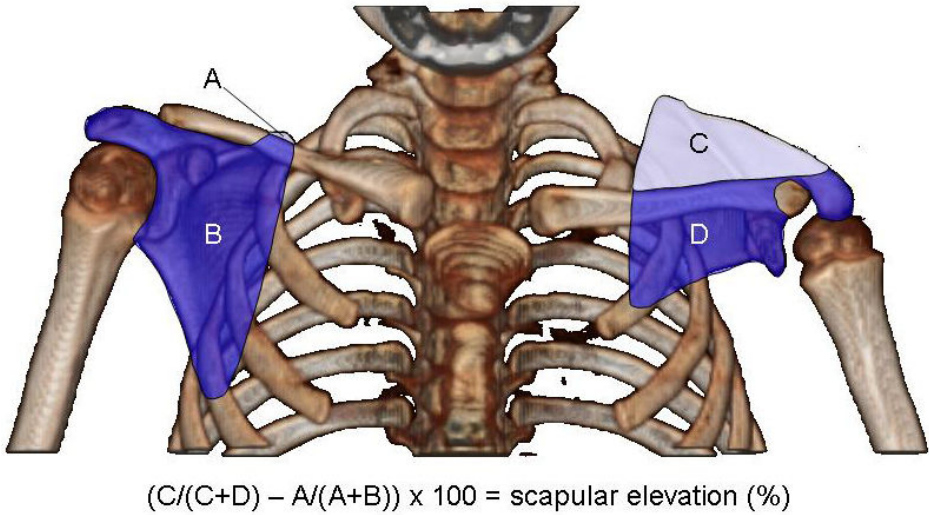


Figure 2. Measuring scapular elevation to quantitate the extent of the SHEAR deformity. Shown here is the CT for a patient with 37% scapular elevation [42].

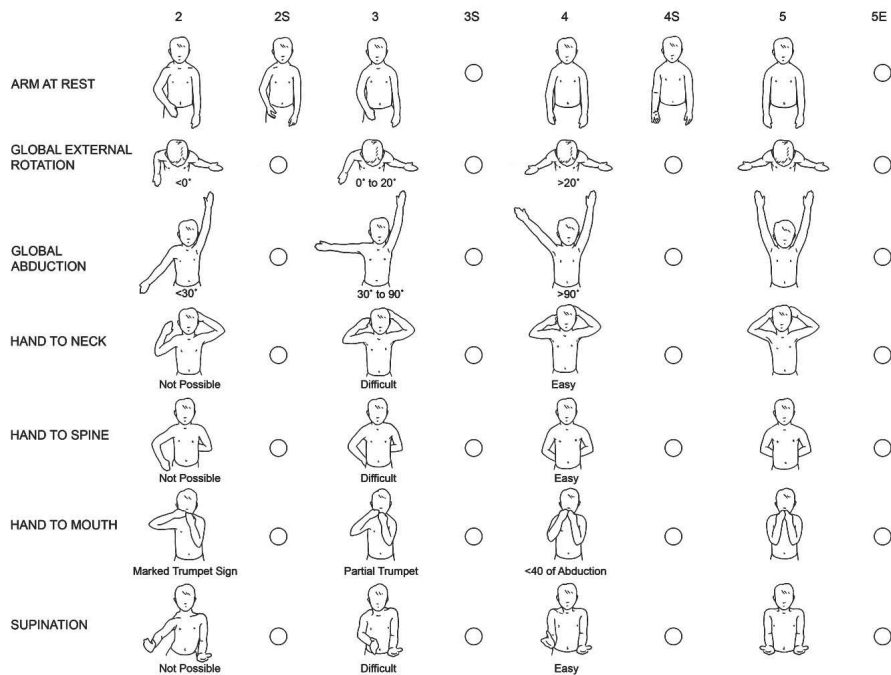


Figure 3. Modified Mallet scale evaluation of function and arm appearance. In addition to assessing the classical shoulder functions of the classical Modified Mallet system, supination and the resting position are evaluated. [19]

3. Non-surgical interventions

Non-Surgical interventions are physical and occupational therapies, electrostimulation, neuromotor therapy, BTX-A injections and splinting. Among the most promising of these methods is BTX-A treatment. This has been shown to treat biceps/triceps co-contraction [30-32], and shown to improve biceps movement and strength [33]. BTX-A treatment for OBPI has not been effective over long-term, in our experience.

4. Primary surgical solutions

There are three primary surgical solutions: neurolysis, neurotization (nerve transfer) and nerve grafting. These may be performed alone or in combination with each other. The choice of which peripheral nerve surgery technique is appropriate is based on which method will maximize

and encourage the natural regenerative process of the nerve. We use nerve transfer and grafting, depending on the intra-operative findings and with our surgical experiences. Injuries of C5-C6 do not always warrant surgery if injury to C7 is minor. In patients where C8 and T1 are involved in addition to C5-C7, hand function is also affected, therefore nerve repair for the upper and middle trunks is more likely to be required.

5. Surgical management

The decision of whether to surgically repair the nerves, however, does typically need to be made in the first 6 months of life. Delay beyond this age in these patients lead to long-term morbidity by causing muscle imbalances and weakness around the shoulder (the deltoid and external shoulder rotators) [34-37], and bony deformities at the shoulder joint (glenohumeral dysplasia and joint incongruity) [20, 38, 39]. These anatomical changes subsequently severely impair the bone growth and development [20]. The major bony deformity that develops is termed as the SHEAR (scapular hypoplasia, elevation, and rotation) deformity, which is caused by the elevation and extrusion of the affected scapula beyond the clavicle [40]. The abnormal anterior rotation of the clavicle together with the protracted scapula causes the acromioclavicular plane to tilt forward and thereby lead to the impingement of the acromion upon the humeral head [41, 42]. Significant secondary deformities that follow include medial rotation contracture (MRC) and elbow flexion.

Early surgical interventions have been shown to improve the limb functions in this group of patients [43, 44]. Management of secondary deformities in OBPI has typically been through the performance of various operative procedures including tendon transfers, muscle releases, axillary nerve decompression, humeral osteotomy, biceps tendon lengthening, glenohumeral capsulorrhaphy and anterior capsule release [45-51].

5.1. Z-lengthening

Biceps tendon lengthening/ the Z-lengthening is an option in C5-C7 (asymmetric) nerve injury, where the biceps recovers faster, thereby overpowering the triceps. The added length that is achieved allows straightening of the elbow and provides additional length to the arm [19].

5.2. Ilizarov bone lengthening

In severe OBPI patients, who is left with severe bony rotational and shortening deformities that are functionally limiting, the use of Ilizarov bone distraction technique is appropriate. This technique is used for rotation and lengthening of the humerus as well as the forearm. Functional gains are significant as the hand is placed into a more useful position [19].

5.3. Posterior glenohumeral capsulorrhaphy

Posterior glenohumeral capsulorrhaphy tightens the posterior capsule surrounding the humeral head and repositions it anteriorly. This procedure does not address the SHEAR

deformity [40] and its central influence in the pathophysiology of the medial rotation contracture. In our experience, on its own, posterior capsulorrhaphy is often not sufficient to address the glenohumeral subluxation, as is predictable when taking the SHEAR into consideration. In our experience, successful restoration of position and function in failed humeral osteotomy patients has followed from surgically addressing the SHEAR deformity. It may be inferred that the SHEAR correction, the Triangle Tilt surgery is a more specific operation because it addresses the root cause of the medial rotation.

6. Muscle and bone deformities and their management

We have been less aggressive to nerve reconstruction and paying more attention to the secondary and tertiary consequences of the initial nerve injury, based on developing and quite compelling literature and on our own experience with several thousand patients [52]. We described our preferred management for muscle injury as a result of OBPI, with supporting clinical and literature evidence. The traditional muscle release operations do not adequately address the pathophysiology of the shoulder in OBPI patients in our experience. Therefore, the surgeon and the lead author (RKN) [53-55] has modified the previously described soft tissue release operation [56], by coupling neurolysis and decompression of the axillary nerve with an untethering release of soft tissue contractures (modified Quad, figure 4) [53-55]. We have demonstrated that modified Quad [53-55] lead to better shoulder abduction and flexion through releasing the existing contractures.

6.1. Modified Quad (figure 4)

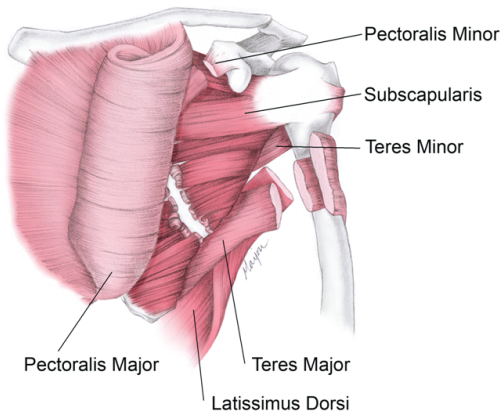
1. Transfer of the latissimus dorsi muscle to give external rotation and abduction.
2. Transfer of the teres major muscle to stabilise the scapula.
3. Release of the subscapularis, pectoralis major and minor contractures.
4. Decompression and neurolysis of the axillary nerve [53, 54].

However, these procedures may not address the glenohumeral dysplasia and joint incongruity. Restoration of glenohumeral congruity is therefore a primary objective in treating OBPI, which then allows for maximum functional range of motion and improved limb growth. A bony surgical procedure, Triangle Tilt (figure 5) [42, 44, 57-66] was therefore developed by the lead author and surgeon (RKN).

6.2. The triangle tilt surgery consists of

1. osteotomy of the clavicle at the junction of the middle and distal thirds,
2. osteotomy of the acromion process at its junction with the spine of the scapula,
3. ostectomy of the superomedial angle of the scapula to reduce scapular winging,

SURGICAL RELEASE OF:
 Pectoralis Minor, Pectoralis Major,
 Teres Major, Latissimus Dorsi,
 and partial release of the Subscapularis



REATTACHMENT OF:
 Teres Major and Latissimus Dorsi
 to Teres Minor

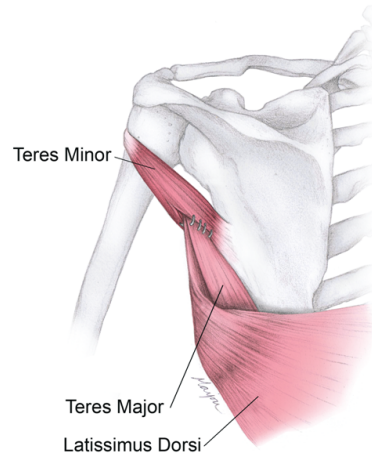


Figure 4. The Mod Quad Procedure improves shoulder abduction and flexion. Left, release of major internal rotator muscles: subscapularis (not shown), teres major, latissimus dorsi, pectoralis major and minor. Right, teres major and latissimus dorsi are transferred to the teres minor, increasing external rotation, abduction and scapular stability. Neurolysis and decompression of the axillary nerve further increase range of motion [19].

4. splinting of the extremity in adduction, external rotation and forearm supination.

This triangle tilt detaches the distal acromio-clavicular triangle-humeral head complex from the abnormally positioned scapula, and tilts the acromio-clavicular plane back to neutral position. This relieves the impingement of the acromio-clavicular triangle on the humeral head. and allows the head to be repositioned passively into a neutral position within the glenoid fossa (Figure 5), resulting in improved gleno-humeral joint congruency [42, 44, 57-66].

We have demonstrated the short (1 year), and long-term (2 years), and extended long term (5 years) benefits of triangle tilt surgery in OBPI patients (age between 0.9 and 17 year old) by examination of their radiological reports as well as the modified Mallet functional scale [42, 44, 57-66]. In addition, triangle tilt surgery is a salvage procedure in failed humeral osteotomy patients [58, 65]. Minor elements of the procedure include bone grafting of the acromion process and clavicular osteotomy sites and semi-rigid fixation of the clavicular osteotomy segments to prevent nonunion [19].

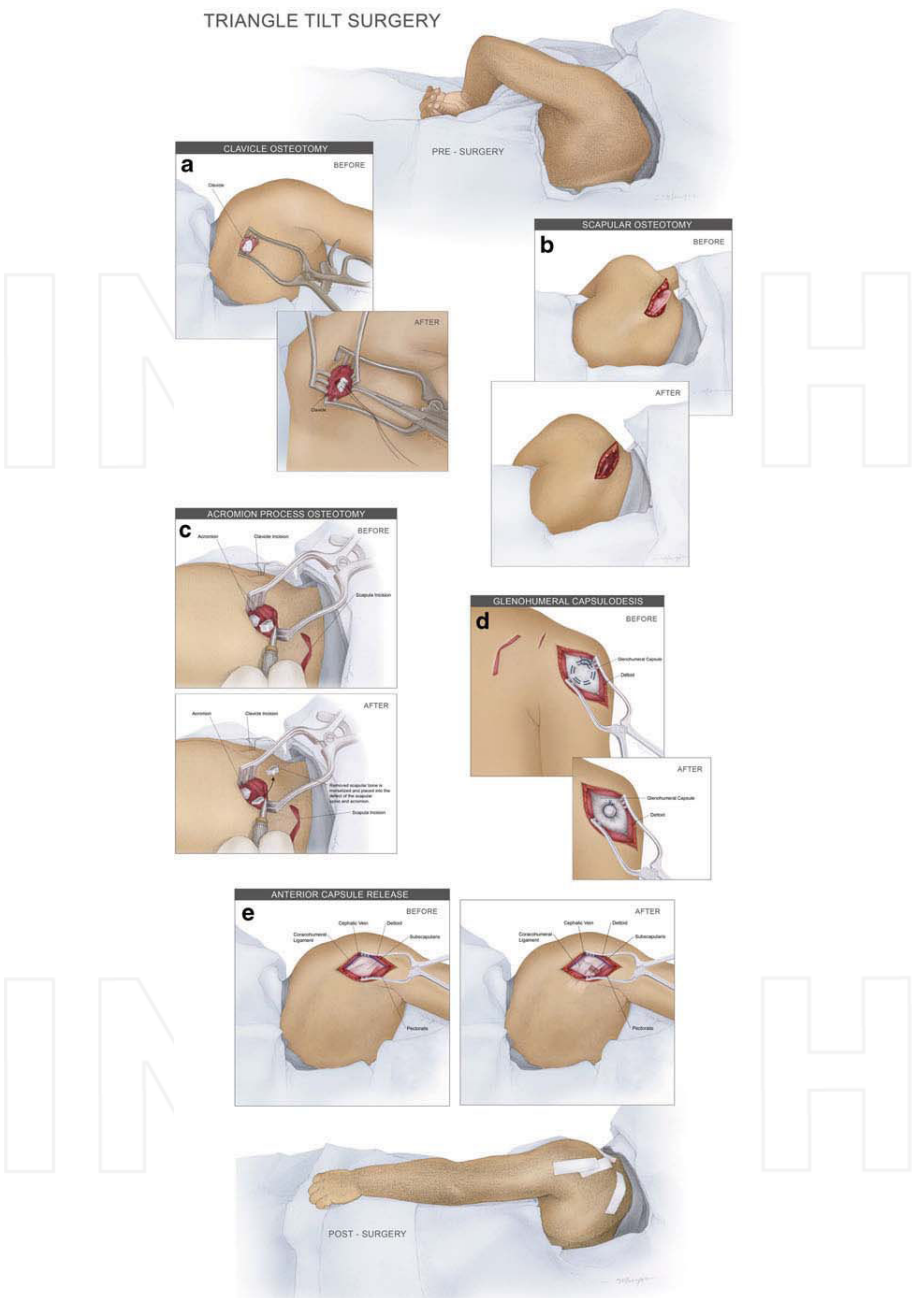


Figure 5. Artist’s rendering of the triangle tilt surgery and anterior capsule release. Illustrated are osteotomies of the clavicle, scapula, and acromion process, along with glenohumeral capsulodesis and anterior capsule release. [19]

7. Conclusions

Based on our own experience with several thousand OBPI patients, we address primarily the muscle and bony operations, and we are less aggressive to nerve reconstruction. These procedures directly address the anatomy of the glenohumeral joint, and thereby resulting in the best possible overall functional outcome. In addition, this minimize the morbidity, expense and the invasiveness of surgery. Nerve reconstruction is reserved for those less common cases where the C5 and C6 nerve roots will not recover.

Modified Quad surgery improves median nerve conduction, and active abduction in young, as well as teen OBPI patients. The triangle tilt surgery improves all shoulder functions significantly in short (1 year), and long-term (2 years), and extended long term (5 years) follow-up, and further the functions are maintained over the extended time in these patients. We recommend that the triangle tilt surgery be performed before the age of 2 years for optimal improvements in outcomes of clinical functioning. This surgery can be performed as early as nine months, and up until late adolescence (16-17 years). Optimal clinical outcomes are achieved if this surgical procedure is performed before the age of 2 years, but improvements in functioning are observed if the surgery is performed after this age as well.

Author details

Rahul K. Nath* and Chandra Somasundaram

*Address all correspondence to: drnath@drnathmedical.com

Texas Nerve and Paralysis Institute, Houston, Texas, USA

References

- [1] Adler JB, Patterson RL, Jr.: Erb's palsy. Long-term results of treatment in eighty-eight cases. *J Bone Joint Surg (Am)* 1967, 49:1052-1064.
- [2] Hoeksma AF, Wolf H, Oei SL: Obstetrical brachial plexus injuries: incidence, natural course and shoulder contracture. *Clin Rehabil* 2000, 14:523-526.
- [3] Foad SL, Mehlman CT, Ying J: The epidemiology of neonatal brachial plexus palsy in the United States. *J Bone Joint Surg (Am)* 2008, 90:1258-1264.
- [4] Gurewitsch ED, Johnson E, Hamzehzadeh S, Allen RH: Risk factors for brachial plexus injury with and without shoulder dystocia. *Am J Obstet Gynecol* 2006, 194:486-492.
- [5] Kay SP: Obstetrical brachial palsy. *Br J Plast Surg* 1998, 51:43-50.

- [6] Zafeiriou DI, Psychogiou K: Obstetrical brachial plexus palsy. *Pediatr Neurol* 2008, 38:235-242.
- [7] Akel BS, Oksuz C, Oskay D, Firat T, Tarakci E, Leblebicioglu G: Health-related quality of life in children with obstetrical brachial plexus palsy. *Qual Life Res* 2013.
- [8] Royal College of Obstetricians and Gynaecologists: Guideline No. 42: Shoulder Dystocia. 2005.
- [9] Jevitt CM: Shoulder dystocia: etiology, common risk factors, and management. *J Midwifery Womens Health* 2005, 50:485-497.
- [10] Mahony R, Foley M, McAuliffe F, O'Herlihy C: Maternal weight characteristics influence recurrence of fetal macrosomia in women with normal glucose tolerance. *Aust N Z J Obstet Gynaecol* 2007, 47:399-401.
- [11] Gherman RB, Chauhan S, Ouzounian JG, Lerner H, Gonik B, Goodwin TM: Shoulder dystocia: the unpreventable obstetric emergency with empiric management guidelines. *Am J Obstet Gynecol* 2006, 195:657-672.
- [12] Rossi LN, Vassella F, Mumenthaler M: Obstetrical lesions of the brachial plexus. Natural history in 34 personal cases. *Eur Neurol* 1982, 21:1-7.
- [13] Tada K, Tsuyuguchi Y, Kawai H: Birth palsy: natural recovery course and combined root avulsion. *J Pediatr Orthop* 1984, 4:279-284.
- [14] Nath RK, Kumar N, Avila MB, Nath DK, Melcher SE, Eichhorn MG, Somasundaram C: Risk factors at birth for permanent obstetric brachial plexus injury and associated osseous deformities. *ISRN Pediatr*, 2012:307039.
- [15] Al-Qattan MM: Obstetric brachial plexus palsy associated with breech delivery. *Ann Plast Surg* 2003, 51:257-264; discussion 265.
- [16] Ubachs JM, Slooff AC, Peeters LL: Obstetric antecedents of surgically treated obstetric brachial plexus injuries. *Br J Obstet Gynaecol* 1995, 102:813-817.
- [17] Gherman RB, Goodwin TM, Ouzounian JG, Miller DA, Paul RH: Brachial plexus palsy associated with cesarean section: an in utero injury? *Am J Obstet Gynecol* 1997, 177:1162-1164.
- [18] Laurent JP, Lee RT: Birth-related upper brachial plexus injuries in infants: operative and nonoperative approaches. *J Child Neurol* 1994, 9:111-117; discussion 118.
- [19] Nath RK: *Obstetric brachial plexus injuries-Erb's palsy: The Nath method of diagnosis and treatment*. College Station, TX: VirtualBookworm.com Publishing; 2007.
- [20] Birch R, Bonney G, Wynn Parry CB: Birth lesions of the brachial plexus. In *Surgical disorders of the peripheral nerves*. Edited by Birch R, Bonney G, Wynn Parry CB. New York, NY: Churchill Livingstone; 1998: 209-233

- [21] Gilbert A, Tassin JL: [Surgical repair of the brachial plexus in obstetric paralysis]. *Chirurgie* 1984, 110:70-75.
- [22] Narakas AO: Obstetrical brachial plexus injuries. In *The paralysed hand. Volume 2*. Edited by Lamb DW. Edinburgh: Churchill-Livingstone; 1987: 116-135: *The Hand and upper limb*].
- [23] Synek VM: Role of somatosensory evoked potentials in the diagnosis of peripheral nerve lesions: recent advances. *J Clin Neurophysiol* 1987, 4:55-73.
- [24] Vredevelde JW, Blaauw G, Slooff BA, Richards R, Rozeman SC: The findings in paediatric obstetric brachial palsy differ from those in older patients: a suggested explanation. *Dev Med Child Neurol* 2000, 42:158-161.
- [25] Colon AJ, Vredevelde JW, Blaauw G, Slooff AC, Richards R: Extensive somatosensory innervation in infants with obstetric brachial palsy. *Clin Anat* 2003, 16:25-29.
- [26] Malessy MJ, Pondaag W, van Dijk JG: Electromyography, nerve action potential, and compound motor action potentials in obstetric brachial plexus lesions: validation in the absence of a "gold standard". *Neurosurgery* 2009, 65:A153-159.
- [27] Malessy MJ, Pondaag W, Yang LJ, Hofstede-Buithuis SM, le Cessie S, van Dijk JG: Severe obstetric brachial plexus palsies can be identified at one month of age. *PLoS One* 2011, 6:e26193.
- [28] Vanderhave KL, Bovid K, Alpert H, Chang KW, Quint DJ, Leonard JA, Jr., Yang LJ: Utility of electrodiagnostic testing and computed tomography myelography in the preoperative evaluation of neonatal brachial plexus palsy. *J Neurosurg Pediatr* 2012, 9:283-289.
- [29] Friedman RJ, Hawthorne KB, Genev BM: The use of computerized tomography in the measurement of glenoid version. *J Bone Joint Surg (Am)* 1992, 74:1032-1037.
- [30] Rollnik JD, Hierner R, Schubert M, Shen ZL, Johannes S, Troger M, Wohlfarth K, Berger AC, Dengler R: Botulinum toxin treatment of cocontractions after birth-related brachial plexus lesions. *Neurology* 2000, 55:112-114.
- [31] Basciani M, Intiso D: Botulinum toxin type-A and plaster cast treatment in children with upper brachial plexus palsy. *Pediatr Rehabil* 2006, 9:165-170.
- [32] Heise CO, Lorenzetti L, Marchese AJ, Gherpelli JL: Motor conduction studies for prognostic assessment of obstetrical plexopathy. *Muscle Nerve* 2004, 30:451-455.
- [33] DeMatteo C, Bain JR, Galea V, Gjertsen D: Botulinum toxin as an adjunct to motor learning therapy and surgery for obstetrical brachial plexus injury. *Dev Med Child Neurol* 2006, 48:245-252.
- [34] Birch R: Late sequelae at the shoulder in obstetrical palsy in children. In *Surgical techniques in orthopaedics and traumatology: Shoulder. Volume 3*. Edited by Randelli M,

- Karlsson J. Paris: Elsevier; 2001: 55-200-E-210: *Surgical Techniques in Orthopaedics and Traumatology*].
- [35] Kon DS, Darakjian AB, Pearl ML, Kosco AE: Glenohumeral deformity in children with internal rotation contractures secondary to brachial plexus birth palsy: intraoperative arthrographic classification. *Radiology* 2004, 231:791-795.
 - [36] van der Sluijs JA, van Ouwerkerk WJ, de Gast A, Wuisman PI, Nollet F, Manoliu RA: Deformities of the shoulder in infants younger than 12 months with an obstetric lesion of the brachial plexus. *J Bone Joint Surg (Br)* 2001, 83:551-555.
 - [37] Nath RK, Mackinnon SE, Jensen JN, Parks WC: Spatial pattern of type I collagen expression in injured peripheral nerve. *J Neurosurg* 1997, 86:866-870.
 - [38] Birch R: Invited editorial: Obstetric brachial plexus palsy. *J Hand Surg (Br)* 2002, 27 B: 3-8.
 - [39] Waters PM: Obstetric Brachial Plexus Injuries: Evaluation and Management. *J Am Acad Orthop Surg* 1997, 5:205-214.
 - [40] Nath RK, Paizi M: Scapular deformity in obstetric brachial plexus palsy: a new finding *Surg Radiol Anat* 2007, 29:133-140.
 - [41] Nath RK, Humphries AD: Computed tomography of the shoulders in patients with obstetric brachial plexus injuries: a retrospective study. *Ann Surg Innov Res* 2008, 2:4.
 - [42] Nath RK, Somasundaram C, Melcher SE, Bala M, Wentz MJ: Arm rotated medially with supination-the ARMS variant: description of its surgical correction. *BMC Musculoskelet Disord* 2009, 10:32.
 - [43] Shenaq SM, Kim JY, Armenta AH, Nath RK, Cheng E, Jedrysiak A: The Surgical Treatment of Obstetric Brachial Plexus Palsy. *Plast Reconstr Surg* 2004, 113:54E-67E.
 - [44] Nath RK, Somasundaram C, Mahmooduddin F: Comparing functional outcome of triangle tilt surgery performed before versus after two years of age. *Open Orthop J* 2011, 5:59-62.
 - [45] Waters PM, Bae DS: The early effects of tendon transfers and open capsulorrhaphy on glenohumeral deformity in brachial plexus birth palsy. Surgical technique. *J Bone Joint Surg Am* 2009, 91 Suppl 2:213-222.
 - [46] Waters PM, Bae DS: Effect of tendon transfers and extra-articular soft-tissue balancing on glenohumeral development in brachial plexus birth palsy. *J Bone Joint Surg (Am)* 2005, 87:320-325.
 - [47] Al-Qattan MM: Latissimus dorsi transfer for external rotation weakness of the shoulder in obstetric brachial plexus palsy. *J Hand Surg (Br)* 2003, 28:487-490.

- [48] El-Gammal TA, Saleh WR, El-Sayed A, Kotb MM, Imam HM, Fathi NA: Tendon transfer around the shoulder in obstetric brachial plexus paralysis: clinical and computed tomographic study. *J Pediatr Orthop* 2006, 26:641-646.
- [49] Pagnotta A, Haerle M, Gilbert A: Long-term results on abduction and external rotation of the shoulder after latissimus dorsi transfer for sequelae of obstetric palsy. *Clin Orthop Relat Res* 2004:199-205.
- [50] Safoury Y: Muscle transfer for shoulder reconstruction in obstetrical brachial plexus lesions. *Handchir Mikrochir Plast Chir* 2005, 37:332-336.
- [51] van der Sluijs JA, van Ouwerkerk WJ, de Gast A, Nollet F, Winters H, Wuisman PI: Treatment of internal rotation contracture of the shoulder in obstetric brachial plexus lesions by subscapular tendon lengthening and open reduction: early results and complications. *J Pediatr Orthop B* 2004, 13:218-224.
- [52] Nath RK, Liu X: Nerve reconstruction in patients with obstetric brachial plexus injury results in worsening of glenohumeral deformity: a case-control study of 75 patients. *J Bone Joint Surg (Br)* 2009, 91-B:649-654.
- [53] Nath RK, Paizi M: Improvement in abduction of the shoulder after reconstructive soft-tissue procedures in obstetric brachial plexus palsy. *J Bone Joint Surg (Br)* 2007, 89:620-626.
- [54] Nath RK, Somasundaram C: Successful outcome of modified quad surgical procedure in preteen and teen patients with brachial plexus birth palsy. *Eplasty*, 12:e54.
- [55] Nath RK, Kumar N, Somasundaram C: Modified Quad surgery significantly improves the median nerve conduction and functional outcomes in obstetric brachial plexus nerve injury. *Ann Surg Innov Res*, 7:5.
- [56] Narakas AO: Muscle transpositions in the shoulder and upper arm for sequelae of brachial plexus palsy. *Clin Neurol Neurosurg* 1993, 95 Suppl:S89-91.
- [57] Nath RK, Karicherla P, Mahmooduddin F: Shoulder function and anatomy in complete obstetric brachial plexus palsy: long-term improvement after triangle tilt surgery. *Child's Nervous System* 2010, 26:1009-1019.
- [58] Nath RK, Avila MB, Karicherla P: Triangle tilt surgery as salvage procedure for failed shoulder surgery in obstetric brachial plexus injury. *Pediatr Surg Int* 2010, 26:913-918..
- [59] Nath RK, Amrani A, Melcher SE, Eichhorn MG: Triangle tilt surgery in an older pediatric patient with obstetric brachial plexus injury. *ePlasty* 2009, 9:e26.
- [60] Nath RK, Amrani A, Melcher SE, Wentz MJ, Paizi M: Surgical normalization of the shoulder joint in obstetric brachial plexus injury. *Ann Plast Surg* 2010, 65:411-417.
- [61] Nath RK, Avila MB, Karicherla P, Somasundaram C: Assessment of triangle tilt surgery in children with obstetric brachial plexus injury using the pediatric outcomes data collection instrument. *Open Orthop J* 2011, 5:385-388.

- [62] Nath RK, Liu X, Melcher SE, Fan J: Long-term outcomes of triangle tilt surgery for obstetric brachial plexus injury. *Pediatr Surg Int* 2010, 26:393-399.
- [63] Nath RK, Mahmooduddin F: Triangle tilt surgery: effect on coracohumeral distance and external rotation of the glenohumeral joint. *Eplasty* 2010, 10:e67.
- [64] Nath RK, Melcher SE, Lyons AB, Paizi M: Surgical correction of the medial rotation contracture in obstetric brachial plexus palsy. *J Bone Joint Surg (Br)* 2007, 89:1638-1644.
- [65] Nath RK, Melcher SE, Paizi M: Surgical correction of unsuccessful derotational humeral osteotomy in obstetric brachial plexus palsy: Evidence of the significance of scapular deformity in the pathophysiology of the medial rotation contracture. *J Brachial Plex Peripher Nerve Inj* 2006, 1:9.
- [66] Nath RK, Somasundaram C, Mahmooduddin F: Triangle tilt and steel osteotomy: similar approaches to common problems. *Open Orthop J* 2011, 5:124-133.

INTECH